

Immune-mediated hepatitis with the Moderna vaccine, no longer a coincidence but confirmed

To the Editor:

We have read with interest the recent cases suggesting the possibility of vaccine-induced immune-mediated hepatitis with Pfizer-BioNTech and Moderna mRNA-1273 vaccines for the SARS-CoV-2 virus.¹⁻⁷ However, as the cohort of vaccinated individuals against COVID-19 increases, the previously reported cases could not exclude a coincidental development of autoimmune hepatitis, which has an incidence of 3/100,000 population per year.⁸ Our case demonstrates conclusive evidence of vaccine-induced immune-mediated hepatitis with a rapid onset of liver injury after the first Moderna dose, which on re-exposure led to acute severe autoimmune hepatitis.

Case description

A 47-year-old Caucasian man, previously completely well, received his 1st Moderna vaccine dose on the 26 April 2021. He noted malaise and jaundice 3 days after. Investigations on the 30th April showed serum bilirubin 190 $\mu\text{mol/L}$ (normal 0-20), alanine aminotransferase (ALT) 1,048 U/L (normal 10-49), alkaline phosphatase (ALP) 229 U/L (normal 30-130), albumin 41 g/L (normal 35-50). Blood count, renal function and international normalized ratio (INR) were normal. Liver function tests (LFTs) last checked 4 years previously were normal. He denied paracetamol use and reported minimal alcohol intake. Ultrasound scan, CT thorax, abdomen and pelvis and MRI pancreas performed to exclude malignancy, showed no significant findings. Serum IgG was raised at 25.1 g/L (normal 6-16), IgM 2.2 g/L (0.5-2) and serum was positive for anti-nuclear antibody. Serological tests for HAV, HBV, HCV, HEV, EBV and CMV were negative.

His jaundice faded and LFTs improved: bilirubin falling on 25th June to 69 $\mu\text{mol/L}$ and ALT to 332 U/L. The patient received his 2nd Moderna vaccine dose on the 6 July 2021 (despite reporting the jaundice to the vaccination centre) and the jaundice returned a few days after. Blood tests on 20th July found bilirubin 355 $\mu\text{mol/L}$, ALT 1,084 U/L and a raised prothrombin time (PT) of 18.4 seconds. After liver biopsy on the 21st July 2021, prednisolone 40 mg/day was commenced and he was transferred to our service.

On examination, he was alert, deeply jaundiced, with hepatomegaly but no ascites. Repeat abdominal ultrasound showed a mildly fatty liver, patent portal and hepatic vein flow, with no ascites. Review of the liver biopsy showed acute active hepatitis: widespread areas of bridging necrosis, marked interface hepatitis, lymphoplasmatic inflammation including eosinophils, ballooned hepatocytes, multi-nucleated giant cells, and emperipolesis (Fig.1). There was minimal fibrosis, Ishak stage 1. The pattern of injury on histology was consistent with acute

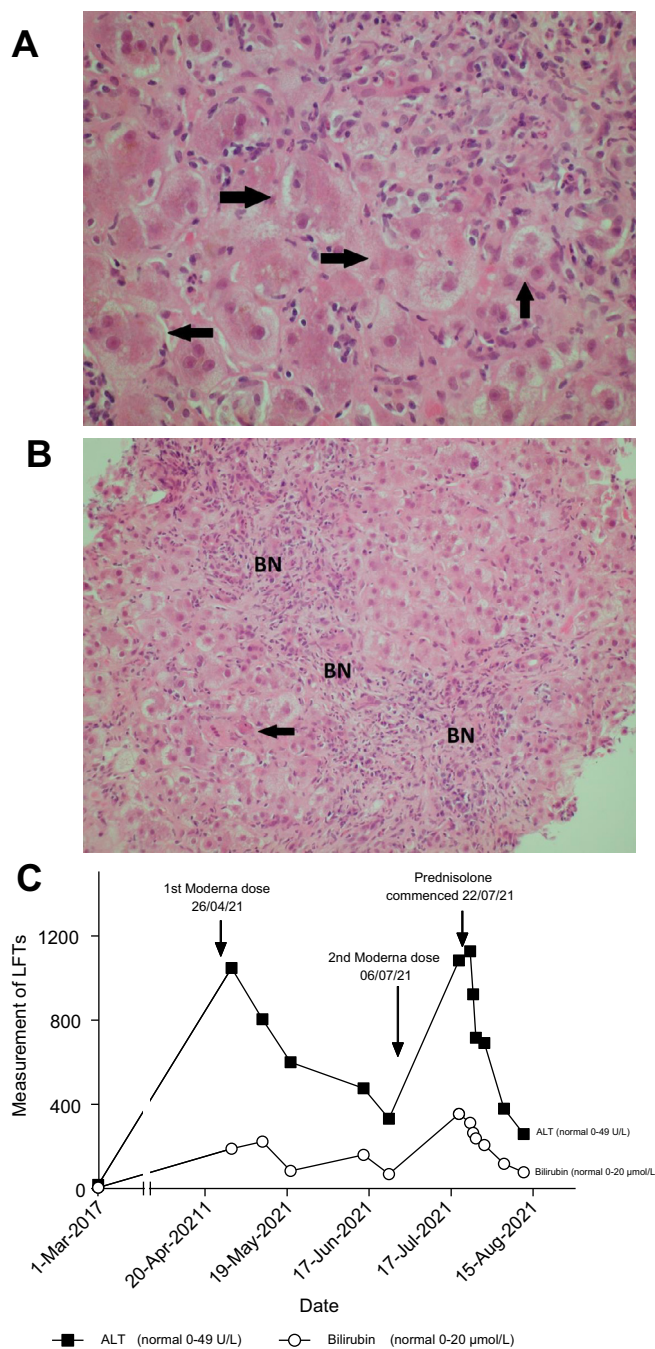


Fig. 1. Histological findings and biochemical findings. H&E-stained section of liver biopsy indicates acute hepatitis. (A) The parenchymal hepatocytes are arranged into rosette forms (marked with arrows) with cholestasis. (B) BN from hepatocyte loss, some by apoptosis (arrow). (C) Diagram showing trend of bilirubin and ALT following Moderna vaccine dose 1 and 2 with response to prednisolone. ALT, alanine aminotransferase; BN, bridging necrosis.

Keywords: Immune-mediated liver damage; drug induced liver injury; autoimmune hepatitis; covid-19.

Received 13 September 2021; received in revised form 22 September 2021; accepted 26 September 2021; available online xxx

<https://doi.org/10.1016/j.jhep.2021.09.031>

Letter to the Editor

hepatitis, with features of autoimmune hepatitis or possible drug-induced liver injury (DILI), triggering an autoimmune-like hepatitis.

Prednisolone 40 mg/day was continued and LFTs improved (Fig. 1). He was discharged on prednisolone and on follow-up, blood tests continue to improve, and PT normalised within 2 weeks.

Discussion

This case illustrates immune-mediated hepatitis secondary to the Moderna vaccine, which on inadvertent re-exposure led to worsening liver injury with deranged synthetic function. This occurred in a well man with no other medical problems. The onset of jaundice associated with the mRNA vaccine was unusually rapid. This was also illustrated in the other cases where symptoms developed over a median of 7 days (range 4-35). Latency is usually longer in other causes of DILI, but can vary depending on mode of injury.

The mRNA vaccine pathway triggers pro-inflammatory cytokines including interferon and cross-reactivity has been illustrated between the antibodies against the spike protein and self-antigens.^{9,10}

Seven cases of suspected immune-mediated hepatitis have been reported with SARS-2-COV mRNA vaccines (3 with Pfizer and 4 with Moderna).¹⁻⁷ Liver histology was assessed in every case and findings were similar to ours, indicating acute hepatitis with interface hepatitis, lymphoplasmacytic infiltrate and absence of fibrosis. Eosinophils as part of the infiltrate, which can be noted in DILI were present in 3 cases. All 7 patients responded well to steroids (n = 5 prednisolone, n = 1 budesonide and n = 1 methylprednisolone). In 3 cases there were features suggesting coincidental autoimmune hepatitis: a 35-year-old lady in her third trimester of pregnancy with positive double-stranded DNA, an 80-year-old lady with a history of autoimmune conditions and a 41-year-old lady with strongly positive auto-antibody panel after both doses of vaccination. In the other 4 cases, a raised IgG, with at least 1 positive antibody was noted in 3 cases.⁴⁻⁷

This case has confirmed immune-mediated hepatitis secondary to the Moderna vaccine, which on inadvertent re-exposure led to acute severe hepatitis. Treatment with corticosteroid therapy appears to be favourable. We wish to highlight that immune-mediated reactions from the SARS-CoV-2 mRNA vaccines are very rare and during the COVID pandemic, the vaccination programme continues to be crucial. We report this case to encourage vigilance for drug-induced reactions and to raise awareness to vaccination centres to incorporate it into their routine checks before administering second doses. Long-term follow up of identified individuals will be essential in determining the prognosis of this immune-mediated liver injury.

Financial support

The authors received no financial support to produce this manuscript.

Conflict of interest

The authors declare no conflicts of interest that pertain to this work.

Please refer to the accompanying ICMJE disclosure forms for further details.

Authors' contributions

DG and AAJ conceptualised the work. GT wrote the initial draft and all authors contributed to and approved the final manuscript.

Supplementary data

Supplementary data to this article can be found online at <https://doi.org/10.1016/j.jhep.2021.09.031>.

References

- [1] Bril F, Al Difalha S, Dean M, Fettig DM, et al. Autoimmune hepatitis developing after coronavirus disease 2019 (COVID-19) vaccine: causality or casualty? *J Hepatol* 2021;75(1):222-224.
- [2] Rocco A, Sgamato C, Compare D, Nardone G, et al. Autoimmune hepatitis following SARS-CoV-2 vaccine: may not be a casualty. *J Hepatol* 2021;75(3):728-729.
- [3] Londono MC, Gratacos-Gines J, Saez-Penataro J. Another case of autoimmune hepatitis after SARS-CoV-2 vaccination. Still casualty? *J Hepatol* 2021. <https://doi.org/10.1016/j.jhep.2021.06.004>.
- [4] Ghielmetti M, Schaufelberger HD, Mieli-Vergani G, Cerny A, et al. Acute autoimmune-like hepatitis with atypical anti-mitochondrial antibody after mRNA COVID-19 vaccination: a novel clinical entity? *J Autoimmun* 2021;123:102706.
- [5] McShane C, Kiat C, Rigby J, Crosbie O, et al. The mRNA COVID-19 vaccine - a rare trigger of Autoimmune Hepatitis? *J Hepatol* 2021. S0168-8278(21)01896-1.
- [6] Tan CK, Wong YJ, Wang LM, Ang TL, et al. Autoimmune hepatitis following COVID-19 Vaccination: true causality or mere association? *J Hepatol* 2021;18. S0168-8278(21)00424-4.
- [7] Lodato F, Larocca A, D'Errico A, et al. An unusual case of cholestatic hepatitis after m-RNABNT162b2 (Comirnaty) SARS-CoV-2 vaccine: coincidence, autoimmunity or drug related liver injury? *J Hepatol* 2021. <https://doi.org/10.1016/j.jhep.2021.07.005>.
- [8] Grønbaek L, Otete H, Ban L, Crooks C, et al. Incidence, prevalence and mortality of autoimmune hepatitis in England 1997-2015. A population-based cohort study. *Liver Int* 2020;40(7):1634-1644.
- [9] Vojdani A, Kharratian D. Potential antigenic cross-reactivity between SARS-CoV-2 and human tissue with a possible link to an increase in autoimmune diseases. *Clin Immunol* 2020;217:108480.
- [10] Tejjaro JR, Farber DL. COVID-19 vaccines: modes of immune activation and future challenges. *Nat Rev Immunol* 2021;21:195-197.

Gloria Shwe Zin Tun*

Dermot Gleeson

Amer Al-Joudeh

Asha Dube

Department of Gastroenterology and Hepatology, Sheffield Teaching Hospitals NHS Foundation Trust, Sheffield, United Kingdom

*Corresponding author. Address: Department of Gastroenterology and Hepatology, Sheffield Teaching Hospitals NHS Foundation Trust, Herries Rd, Sheffield, S5 7AU United Kingdom; Tel.: 0114 2715414,

fax: 0114 3052843.

E-mail address: g.tun@nhs.net (G.S. Zin Tun)